

Figure 16-16. Giant cell tumor. Image courtesy of John M. Rayhack, MD.

**35. Digital mucous cysts are typically present with all of these characteristics except:**

- A. Found at the DIP joint or in the proximal nail fold
- B. Round to oval, dome shape
- C. Lunula discoloration
- D. Occurs in the 2nd and 3rd decade of life

Mucous cysts (Figure 16-17ABC) typically occur between the fifth and 7th decades. These cysts most frequently occur on the dorso-lateral aspect of the fingers, between the DIP joint and the nail fold. They are most frequently found on the index or middle digit of the dominant hand and present with lunula discoloration.

» **Answer: D**

Rizzo M., *Journal of Hand Surgery*, pp. 19-524.

Athanasian, E.A., *Green's Operative Hand Surgery*, pp. 2005-2006

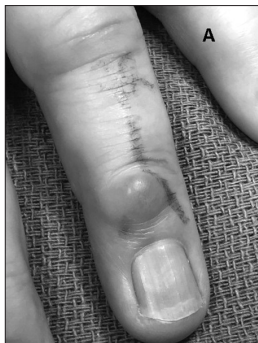

Figure 16-17ABC. Images courtesy of John M. Rayhack, MD.

Figure A: Mucous cyst.

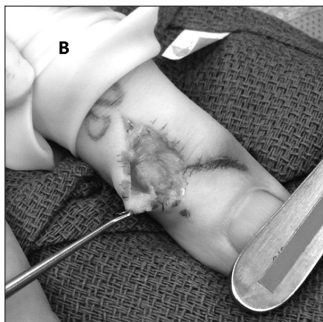


Figure B: Surgical resection of the cyst.

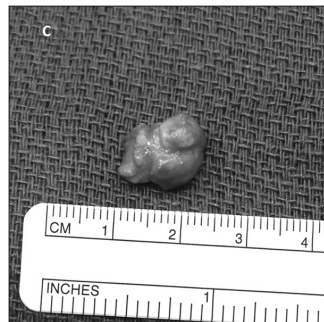

Figure C: Excised mucous cyst.

**36. True or False: A lipoma is typically a painless tumor composed of adipose tissue which can arise any place in the body where there is adipose tissue.**

Lipomas (Figures 16-18AB) are fairly common, and are typically painless until they become large. They vary in size depending on where they are found in the body. In the hand, the deep palmar space is the most common place to find them, and they are usually found in intramuscular locations within the intrinsic muscles. Palmar lipomas can compress the median nerve, resulting in symptoms of carpal tunnel syndrome.

» **Answer: True**

Sweet, S., Kroonin, L., Weiss, S., *Rehabilitation of the Hand and Upper Extremity*, pp. 294.

Figure 16-18AB. Images courtesy of John M. Rayhack, MD.

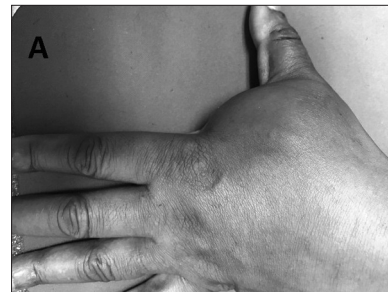


Figure A: Lipoma from dorsal view.

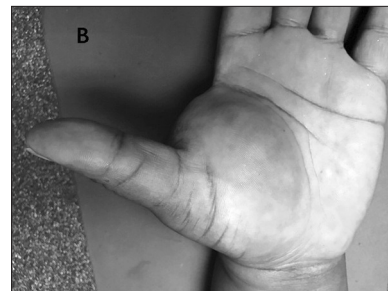


Figure B: Volar view of the lipoma.

**62. A 30-year-old male patient sustained a traumatic right transhumeral amputation. Which device is the best choice in order to maximize his functional independence?**

- A. A myoelectric hand because of its cosmesis and functional abilities
- B. A conventional body-powered voluntary opening hook because of the increased ability to visualize objects during functional use
- C. A passive cosmetic prosthetic because his nondominant extremity was amputated
- D. None of the above

No absolutes exist in prosthetic prescription as individually each patient must be evaluated to determine individual physiologic, anatomic, and psychological needs, as well as preferences, routines, and roles in daily occupational performance. A multi-disciplinary team approach is encouraged for the prescriptive pattern as individual needs and preferences continue to prevail.

» **Answer: D**

Keenan, D. D., Glover, J.S., *Pedretti's Occupational Therapy*, pp. 1095-1138.  
Migueluez, J., Migueluez, M., Alley, R., *Atlas of Amputations and Limb Deficiencies*, pp. 263-273.

» **CLINICAL GEM:**

The right terminal device for the right task allows the end user to get back to activities that he loved before his amputation!



Figure 17-20. Photo courtesy of Hanger Clinic, [www.hangerclinic.com](http://www.hangerclinic.com).

**63. During embryonic limb development, the arm buds and the leg buds are \_\_\_\_\_**

- A. Controlled by different signaling centers to produce the distinct characteristic of the forelimb and the hindlimb.
- B. Well formed by day 22.
- C. Controlled by Hosmer-Dorrance hormones.
- D. Controlled by the same key signaling centers.

Genes and signaling centers for limb development are the same for the forelimb and the hindlimb. Two different structures are produced by common signaling cascades. The forelimb and hindlimb buds are both derived from regions of the lateral plate mesoderm. The limb buds are a collection of cells that develop into distinct limb elements. Patterning of each limb is controlled by key signaling centers of the apical ectodermal ridge (AER). In the developing limb bud, the cells are coordinated from three signaling centers to produce the characteristics of the forelimb and the hindlimb. Cells in the hindlimb respond to the same signals as the cells in the forelimb, but produce different structures. The arm bud is well developed by days 28-30. (Figure 17-21)

» **Answer: D**

Logan, M., *Development*, pp 6401-6404.  
Sheth, R., *Science*, pp. 1476.  
Keith, A., *Book-Human Embryology & Morphology*.  
Johnson J., Moonis, Green, Carmody, Burbank, *American Journal of Neuroradiology*, pp. 14-19.

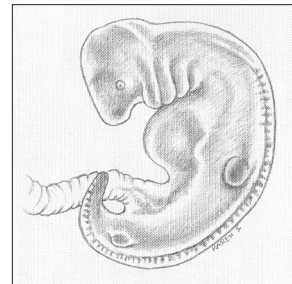


Figure 17-21. Well developed arm bud illustration courtesy of Karen Lynn Sitarik.

» **CLINICAL GEM:**

During days 34-38 elongation of arm buds and leg buds begin. After elongation of the limb buds, the hand and foot plates form and delineate into rays. Separation of rays begins from apoptosis (the process of programmed cell death). By day 52 full finger separation is seen and moderate notching between the toes are emerging. By day 56 toe separation is seen. The fingers separate four days earlier than the toes. (See figure)

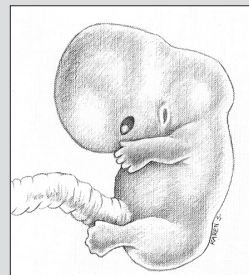


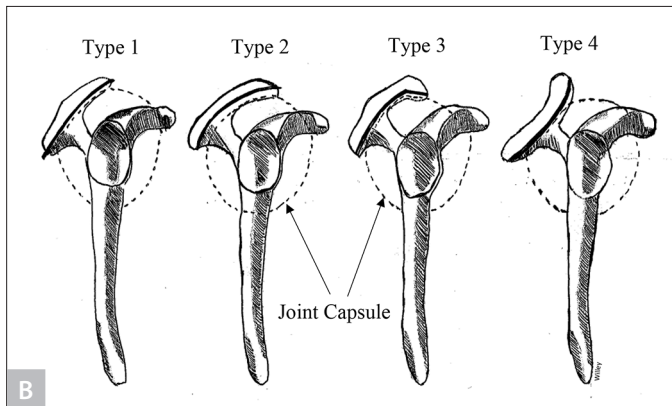
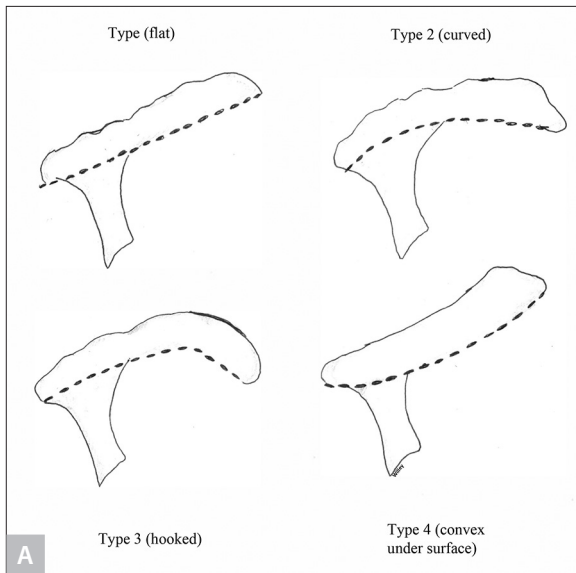
Figure 17-22. Full separation of digits in the hand by day 52, toes show the beginning of separation. Illustration courtesy of Karen Lynn Sitarik.

often associated with rotator cuff tears because the impingement caused by the anterior curving or hooking leads to degeneration and tearing of the rotator cuff.

Approximately 3% of the population demonstrates a convex (upturned) acromion shape, which has been classified as Type 4. The undersurface of a type 4 acromion is convex near the distal end and demonstrates no correlation with impingement. (Figure 21-8AB)

» **Answer: C**

Bigliani, L. U., Ticker, J. B., Flatow, E. L., Soslowky, L. J., Mow, V. C., *Clinics in Sports Medicine*, pp. 823-838.



**Figure 21-8 A-B:** A: Acromial morphology. B: Acromion shapes. Photos courtesy of Marc S. Willey, PhD, OTR/L, CHT.

» **CLINICAL GEM**

An estimated 70% of all rotator cuff tears occur in patients with a Type 3 acromion.

## 22. What is rotator cuff arthropathy?

- A. Diffuse weakness of the rotator cuff
- B. A transient pain related to the rotator cuff
- C. A combined deficiency of the rotator cuff with glenohumeral arthrosis
- D. An advanced case of calcific tendinitis

Rotator cuff arthropathy is a degenerative condition in which a deficient/torn rotator cuff allows the humeral head to migrate superiorly and arthrosis develops.

» **Answer: C**

O'Brien, J., Leggin, B., Williams, G., *Rehabilitation of the Hand and Upper Extremity*, pp. 1158-1159.

**23. A 50-year-old patient presents to an orthopedic surgeon with a 6-month history of severe shoulder pain without any history of injury. The range of motion of the shoulder is diminished by approximately 50%, and testing is positive for impingement. The patient also exhibits a positive drop-arm test. The patient refuses any type of injections or medicines. What should the surgeon do next?**

- A. Order immediate occupational/physical therapy
- B. Instruct the patient in a home exercise program
- C. Order an arthrogram
- D. Order an MRI

The best choice for this patient would be to order an MRI for evaluation of the rotator cuff. Evaluation of the cuff would be essential before deciding on further treatment. Occupational or physical therapy would likely aggravate the pain at this stage and therefore is not indicated. A home exercise program most likely would be ineffective because this may also aggravate the pain. An arthrogram involves injecting a spinal needle into the shoulder joint under fluoroscope followed by the injection of a contrast medium to diagnose possible labral pathology. Since the patient refuses any type of injection, this test would not be possible.

» **Answer: D**

Shortt, C., Morrison, W. *Rehabilitation of the Hand and Upper Extremity*, pp. 178.

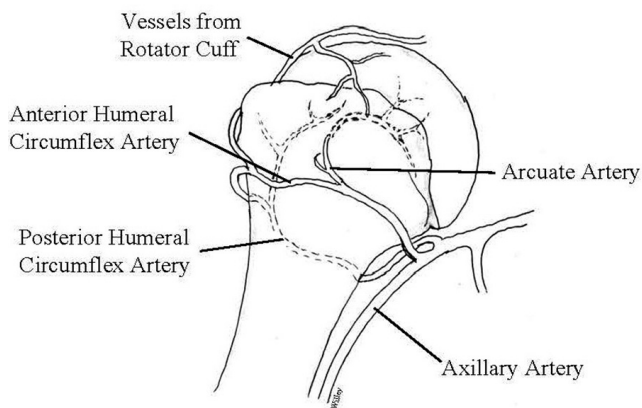
**61. Which of the following fractures presents a considerable danger to the surrounding nerves and vessels?**

- A. Epiphyseal fracture
- B. Humeral shaft fracture
- C. Proximal humeral fracture
- D. Distal humerus fracture

Because of the proximity of the axillary blood vessels and the brachial plexus, a fracture to the proximal humerus may result in severe hemorrhaging or paralysis. (Refer to Figure 21-25)

» **Answer: C**

Bakei, D. P., Taitzman, L., Nork, S. K., *Hand, Elbow, and Shoulder Core Knowledge in Orthopedics*, pp. 615.



**Figure 21-25:** Shoulder proximal blood supply. Photo courtesy of Marc S. Willey, PhD, OTR/L, CHT.

» **CLINICAL GEM**

Recognizing a fracture of the upper humerus by visual inspection may be difficult; therefore, radiographs are mandatory.

**62. Which of the following is NOT an example of a closed chain exercise that would be appropriate to use in therapy with a patient who is 12 weeks post non-operative humeral fracture?**

- A. Use of a tilt board for weight bearing in quadruped
- B. Weighted cane exercises in supine for flexion and abduction
- C. Ball rolling against the wall
- D. Seated press ups
- E. Wall push ups

Using a weighted cane for exercise in supine for flexion and extension is an open chain exercise. Open chain exercises are defined as working against resistance where the extremity is free to move in space resulting in movement of the distal segment. Closed chain exercises are defined as working against resistance with the extremity working against a stationary or mobile but motion-constrained object or surface. The other four choices are all closed chain exercises.

» **Answer: B**

Butler, M., *Fundamentals of Hand Therapy*, pp. 164.

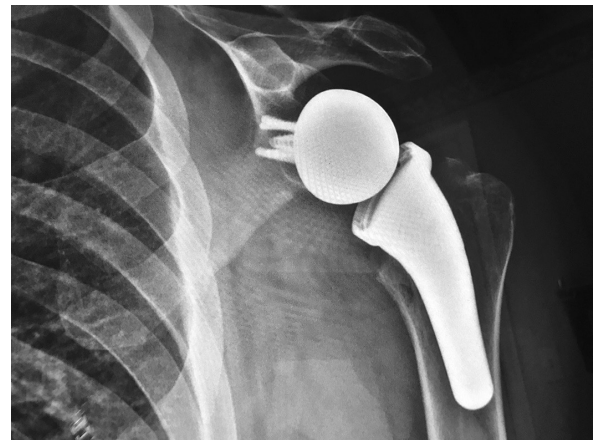**63. What is depicted in this picture?**

- A. Shoulder arthroplasty
- B. Shoulder arthrodesis
- C. Total shoulder replacement
- D. Reverse total shoulder replacement

In a reverse total shoulder replacement, the ball and the socket of the implant are reversed. The ball is on the glenoid side and the socket is on the humeral side. This surgery has only been made available in the United States since 2004.

» **Answer: D**

Tan, V, Leggin, B, Kelley, M, Williams, G., *Rehabilitation of the Hand and Upper Extremity*, pp. 1417.



**Figure 21-26:** Photo courtesy of Loren Szmiga, PT, DPT, CHT, MTC.

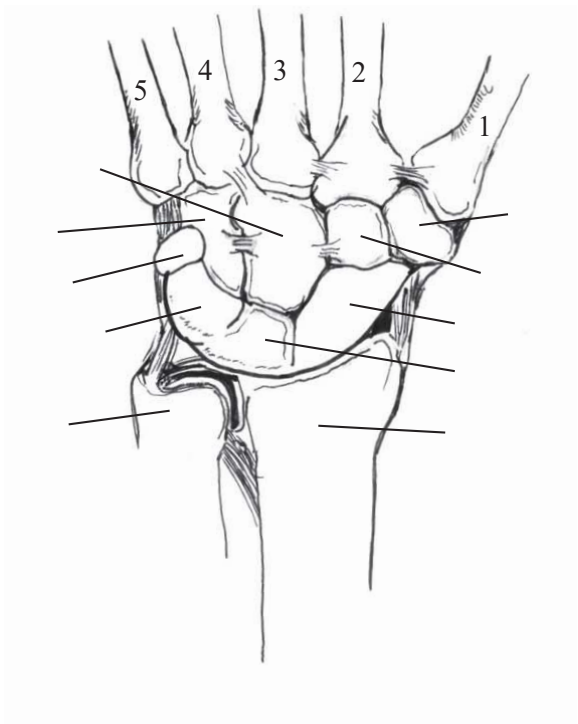
» **CLINICAL GEM**

A good candidate for a reverse total shoulder replacement would be a person with end stage severe rotator cuff arthropathy, severe OA, elderly, have a low demand with acute elevation less than 120 degrees, a deltoid that is functional, and must have sufficient bone on the glenoid side to allow for secure screw fixation of component.

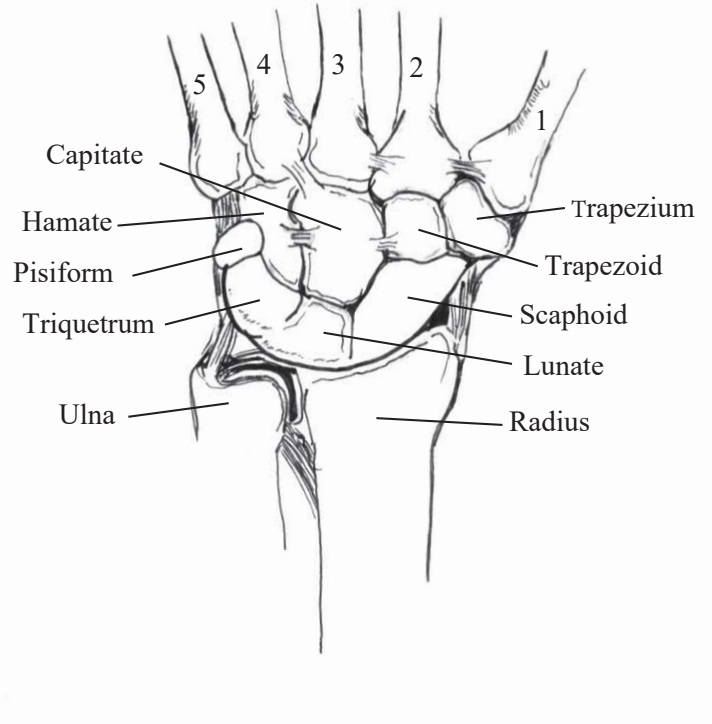


### Wrist Anatomy

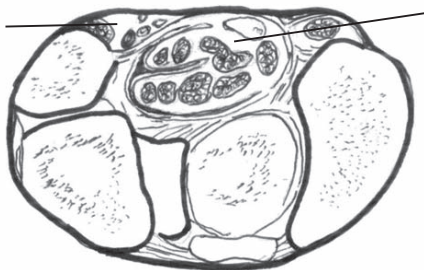
**Carpal Bones Unlabeled**



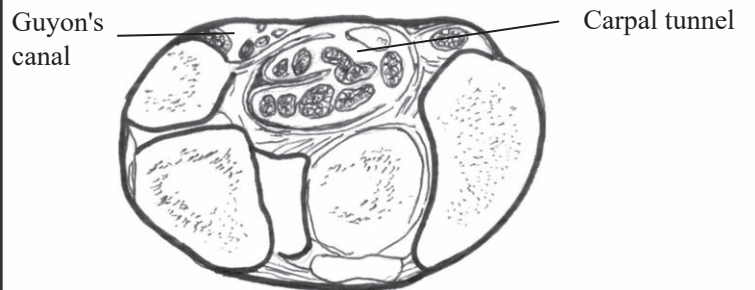
**Carpal Bones Labeled**



**Wrist Slice Unlabeled**



**Wrist Slice Labeled**



## Appendix 6

# Tendon Transfers

Dr. Shovan Saha, MOT (Hand Rehabilitation), PhD

A tendon transfer is a surgical procedure to redirect an active and viable motor towards another dysfunctional motor to produce meaningful movements. The process has to fulfill certain mechanical requirements and appropriate donor-recipient selection and should be followed by a focused rehabilitation program.

### Important mechanical considerations of tendon transfers:

1. Tendon transfers restore impaired motor function.
2. A transferred muscle needs daily use, active contraction and the application of the patient's recognition of the new function of the muscle.
3. The outcome is reflected by the mechanical qualities of the paratendinous scar.
4. The importance of a stable, functioning wrist is important for success in many transfers.

### Excursion of Muscle:

The excursion is the maximum linear movement of the transferred muscle and should be adequate to achieve the desired movement in the hand.

1. The **potential excursion** is when muscle contracts from its fully stretched position through a distance that is approximately equal to its resting length.
2. The **required excursion** is the length needed to put the joints through their whole range.
3. The **available excursion** is the extent to which the joints and muscles have stretched during the previous months.

### Indications for Tendon Transfer:

The absence of a particular needed function for a period of four to six months after irreparable nerve injury, nerve disease, or muscle loss.

### Basic Requirement for Tendon Transfer:

1. **Joint mobility:** The participating joints should be freely capable of passive motion.
2. **Adequate soft tissue coverage:** Well-healed and pliable soft tissues must be present.
3. **Available motor tendons:** A donor muscle must be available.

### Selection of a Motor Tendon for Transfer:

1. **Amplitude:** Amplitude of approximately 40% of resting length of the donor tendon is a prime factor in tendon selection. For example, full finger extension at the metacarpophalangeal (MCP) joints requires 5 cm of amplitude while the flexor digitorum profundus (FDP) needs an amplitude of 7 cm for full flexor function.
2. **Power:** When a muscle-tendon unit is transferred, its strength drops one level on a scale of 0 to 5; therefore, accurate pre-operative muscle testing is essential.
3. **Direction:** The pathway of the transferred muscle should be as straight as possible to its new insertion.
4. **Phase:** When muscles perform synergistically they are said to function in phase, like wrist extensors and digital flexors or wrist flexors and digital extensors.
5. **Immobilization:** Plaster immobilization is applied for 3 to 4 weeks before removal for exercises. Typically, orthotic protection is added for an additional 3 weeks.

## Appendix 7

# Critical Concepts to Commit to Memory

Edited by Aida E. Olvera-Dyckes OTR/L, MSOP, CHT, CLT

This appendix will allow you to create an auditory learning program. Read these bullet points into a recording device and then play them back while driving to work, waiting on patients, or exercising. Some studies indicate that we retain information better by hearing than by seeing. These bullet points are fabulous tidbits to hear and remember. They are presented in no specific order. They were submitted by therapists from around the world who have prepared for and passed the CHT<sup>®</sup> exam. Please visit [handtherapy.com](http://handtherapy.com) to add additional audio experiences to your learning portfolio.

- Ligaments attach bone to bone.
- Tendons attach muscle to bone.
- A flat fist (straight fist—PIP flexed with DIP extended) allows for maximum flexor digitorum superficialis glide.
- A hook fist allows for the maximal differential glide between flexor digitorum superficialis and flexor digitorum profundus.
- A full fist (composite) allows for maximal flexor digitorum profundus glide.
- The tabletop position is dependent upon intrinsic contraction.
- The proper collateral ligaments of the MCPJ are taught in flexion and are on slack in extension and the accessory collateral ligaments at the MCP are more volar and taut in extension and are on slack in flexion.
- \* Middle phalanx fractures distal to the insertion of the FDS angulate with a volar apex.
- \* Middle phalanx fractures proximal to the insertion of the FDS angulate with a dorsal apex.
- Spiral fractures and oblique fractures tend to rotate and become unstable unless fixated.
- Comminuted open fractures involve greater damage to surrounding soft tissue.
- Conventional TENS setting: High frequency 50-100 Hz, short pulse duration 40-75 microseconds, 10-30 milliamp, 20 minutes.
- Outriggers should be at 90 degree angles of pull on the long axes of the bones on which they are acting.
- When you flex the digits independently at the MCP level each line up closely with the scaphoid if no rotational deformity or malalignment is present.
- A lateral epicondylitis orthotic should place the wrist in approximately 20-30 degrees of extension.
- A counterforce strap works by dispersing extensor muscular force across the tendon and decreasing the amount of force that can be generated.
- Clinodactyly affects the small finger DIPJ which is fixed in flexion and in the palmar or radio-ulnar plane.
- Camptodactyly causes a PIPJ flexion contracture in the sagittal or flexion/extension plane.
- Start prosthetic training (usually a passive terminal device) on a baby at 6 months.
- Training in the use of a myoelectric prosthetic can start as early as 18 months to 2 years.
- Body powered terminal devices typically start at 18-24 months for children.
- A voluntary opening terminal device requires body power to pull on a cable.
- A V-Y advanced flap is used to treat fingertip amputations.
- The priority of thumb reconstruction is opposition and sensation.
- The thumb is responsible for 40-50% of hand function.
- Typical hand posturing deformity following complex trauma: MCP extension, wrist and IP flexion, and thumb adduction.





Saint Petersburg, FL

HAND AND UPPER EXTREMITY REHABILITATION:  
A QUICK REFERENCE GUIDE AND REVIEW,  
FOURTH EDITION

ISBN: 978-0-9884606-8-3

Library of Congress Control Number: 2018940981

Copyright © 2019, EXPLORING HAND THERAPY, Inc.©

All rights reserved.

This publication may not be reproduced or transmitted in any form or by any means, electronic or mechanical, including photocopying, or duplication of any kind, without express written permission from the publisher.

NOTICES: Knowledge and best practice in this field are constantly changing. We are aware of the many techniques available to treat particular pathologies and realize this book may present debatable material. We have made every effort to verify the content and the answers to all of the questions. References are provided to clarify and expand on controversial points. The material presents the technique, view, statement, or opinion of the authors and contributors, which is helpful and interesting to other practitioners. We have made every effort to ensure that the therapeutic interventions, appendix material, pharmaceuticals and modalities recommended are in accordance with accepted standards current at the time of this publication. It is the practitioner's responsibility to rely on his or her own experience and knowledge of patient care to take all appropriate safety precautions and to evaluate the appropriateness of a particular opinion in clinical situations. To the fullest extent of the law, the Publisher, Authors and Editors assume no liability for any injury and/or damage to persons or property arising out of or related to any use of the material herein. Partial funding of this book was from the generosity of our vendors included in the appendix and with the use of photos throughout the text. Additionally, one of the uses of this text is to assist readers with review and preparation for the CHT® exam; "The 'CHT' credential is a registered trademark of the Hand Therapy Certification Commission ('HTCC'). These materials, while representative of the type of knowledge and skills tested on the Hand Therapy Certification Exam, do not necessarily mirror the content of the exam. HTCC has not participated in the development of these materials and does not endorse or recommend them. The information, views, and/or opinions expressed in these materials are not those of HTCC."

Previous editions copyrighted 1999, 2005 and 2013

*Chief Developmental Editor:* Susan Weiss, OTR/L, CHT

*Senior Project Manager:* Laurie C. Rogers, MHS, OT, CHT

*First Editorial Assistant:* Micah Bingham, OTR/L, CHT

*Second Editorial Assistant:* Erin Conner, MS, OTR/L, CHT

*Illustrators 4th Edition:* Marc S. Willey, PhD, OTR/L, CHT, Karen Lynn Sitarik,

Michelle Saksa, OTR, OTD, CHT, GTS

*Illustrators 3rd Edition:* Oliver Norden, Michelle Reiner, Rudy Paul, Jan Cervone, Anita Smith

*Design Manager:* Kathy Campbell

*Cover Drawing:* Tammy R. McKee, MS, OTR/L, CHT

Printed in the United States of America